

BILL IMPACTION IN A GROUP OF CAPTIVE CARIBBEAN FLAMINGOS (*PHOENICOPTERUS RUBER RUBER*)

Sven Hammer, Dr. Med. Vet., Cert. Zoo. Anim. Spec. (Germany), Simon Jensen, Raffy Borjal, D.V.M., Marcus Clauss, M.Sc., Dr. Med. Vet., Dipl. E.C.V.C.N.

Abstract: Flamingos are filter feeders that only rarely ingest larger food items. Their bill anatomy is adapted to the suction, filtration, and ejection of a fluid medium. This case report documents a rare case of bill impaction in a group of Caribbean flamingos (*Phoenicopterus ruber*) that were kept in a mixed exhibit together with roseate spoonbills (*Platalea ajaja*) and scarlet ibis (*Eudocimus ruber*). The latter species received fatty minced meat as part of their diet, which was also accessible to the flamingos. Weakness and poor body condition of one flamingo were noted. On clinical examination, the animal was emaciated, hypoglycemic, and showed a severe impaction of the bill with a mixture of lard, mud, and sand. This mixture had compressed the tongue and eventually had most likely prevented further food intake. In five additional flamingos, a bulging of the gular area, similar to the extension of this area during the tongue-retraction stage of the feeding cycle, was noted and interpreted as a sign of tongue displacement by similar masses in their bills. All animals were caught and the masses removed. All animals resumed food intake immediately, and the emaciated animal rapidly improved in condition. Food presentation was changed so that the trays for the other species were no longer accessible to the flamingos, and no similar problems have been observed since that time.

Key words: Filter feeding, nutrition, flamingo, mixed exhibit, fat, tongue.

INTRODUCTION

Flamingos are filter feeders with a unique but highly specialized bill anatomy.^{1,6} In healthy birds, the tongue normally fits tightly into the cavity of the mandible, filling it almost completely, with the exception of a small area at the anterior end (Fig. 1). During feeding, the tongue acts as a piston that creates suction and pressure within the beak to attract and eject water into and out of the beak. As the tongue cannot be compressed and the rostral portion of the lower mandible is rigid, the tongue, when withdrawn, bulges the gular region (the soft area posterior to the rigid part of the lower mandible).⁶ Thus, during feeding, two different stages of distension of the gular region follow each other in rapid sequence (Fig. 2).

Bill anatomy varies among the different flamingo species; this anatomy is associated with the size of the filtered particles targeted by the respective species.^{1,3,4,6} Whereas some species with more shallow bills, such as *Phoenicopterus ruber* and *Phoenicopterus chilensis*, feed on small mollusks and crustaceans, species with deeper bills, such as *Phoenicoparrus sandinus* and *Phoeniconaias minor*, feed

mainly on diatoms and algae.⁴ In captivity, flamingos are usually fed commercial, complete diets of extruded pellets that float on the water surface.⁴ Historically, different gruel mixtures, including grain meals, shrimp and fish meal, alfalfa meal, seaweed, and other ingredients, have been used.⁵ However, older reports even mention that apart from such gruels, raw and cooked meat and small pieces of fish have been fed to flamingos.²

This case report documents an incidence of bill impaction in a group of Caribbean flamingos; the impaction was due to the access to food intended for other species maintained in a multispecies exhibit. This case demonstrates the relevance of the physical characteristics of the diet offered to these birds and the use of anatomic descriptions in the clinical diagnosis of specialized animals.

CASE REPORT

Case history

A group of 17 female Caribbean flamingos has been on display at the Al Wabra Wildlife Preservation (Doha, State of Qatar) since 1998. This group shared a two-pond enclosure (40 × 20 m) with a breeding group of roseate spoonbills (*Platalea ajaja*) and scarlet ibis (*Eudocimus ruber*). The flamingos had been maintained consistently on a commercial, pelleted diet (Altromin Z1015; Altromin, Lage, Germany) together with a coloring agent (Necton R; Necton, Pforzheim, Germany); both were offered soaked in water dishes at ground level. The ibises and spoonbills received a common

From the Al Wabra Wildlife Preservation, Sheik Saoud Bin Mohd. Bin Ali Al Thani, P.O. Box 44069, Al Wabra, Doha, State of Qatar (Hammer, Jensen, Borjal); and the Division of Zoo Animals, Exotic Pets and Wildlife, Vetsuisse Faculty, University of Zurich, Winterthurerstr. 260, 8057 Zurich, Switzerland (Clauss). Correspondence should be directed to Dr. Clauss.




Figure 1. Normal view of the tongue and lower mandible of a Caribbean flamingo (*Phoenicopterus ruber*) and view of the tongue when positioned out of the lower mandible in our case.

diet of defrosted shrimps, dog biscuits (Pedigree Meaty-bites®; Masterfoods, Raglan, New South Wales, Australia), a variety of sliced fish and chicken, mealworms, and the same pellets and coloring agent as the flamingos. Additionally a commercial minced meat preparation (Al Safeer minced beef; Nashar Meat Company, Jeddah, Saudi Arabia), which contained 50% fat, according to the manufacturer, was added to the diet. The dishes for these other species were also placed at ground level. Occasionally, consumption of the minced meat by the flamingos had been observed but had been judged negligible.

In January 2006, one flamingo in the group was noted to appear to be weak, with difficulties in standing. The bird was caught and restrained man-

ually and transported to the veterinary hospital for clinical workup.

Clinical examination

On clinical examination, the bird appeared in poor body condition, with a very prominent keel bone. Body weight was 1.30 kg. Wet, unkempt feathers were considered another sign of generalized weakness. No abnormalities were discovered by inspection, palpation, or auscultation, with the exception of a greasy layer on the outside of the upper and lower mandibles (Fig. 3) and the presence of a hard, black, greasy mass consisting of a mixture of mud, sand, and grease, located inside of the lower mandible (Fig. 4). The mass caused the tongue of the animal to be pushed backwards, with

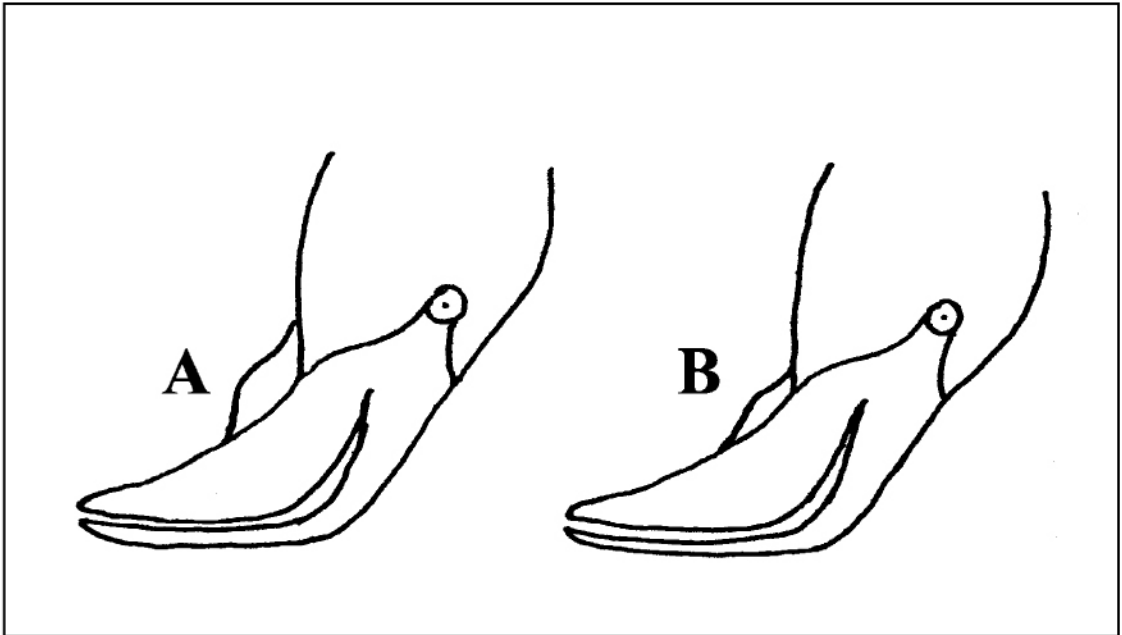


Figure 2. Modified schematic drawing⁶ of two stages of tongue placement during feeding in flamingos. **A.** For suction of fluid into the bill, the tongue is retracted, bulging the gular area. **B.** For ejection of fluid, the tongue is replaced into its normal resting position, and the bulging of the gular area disappears.

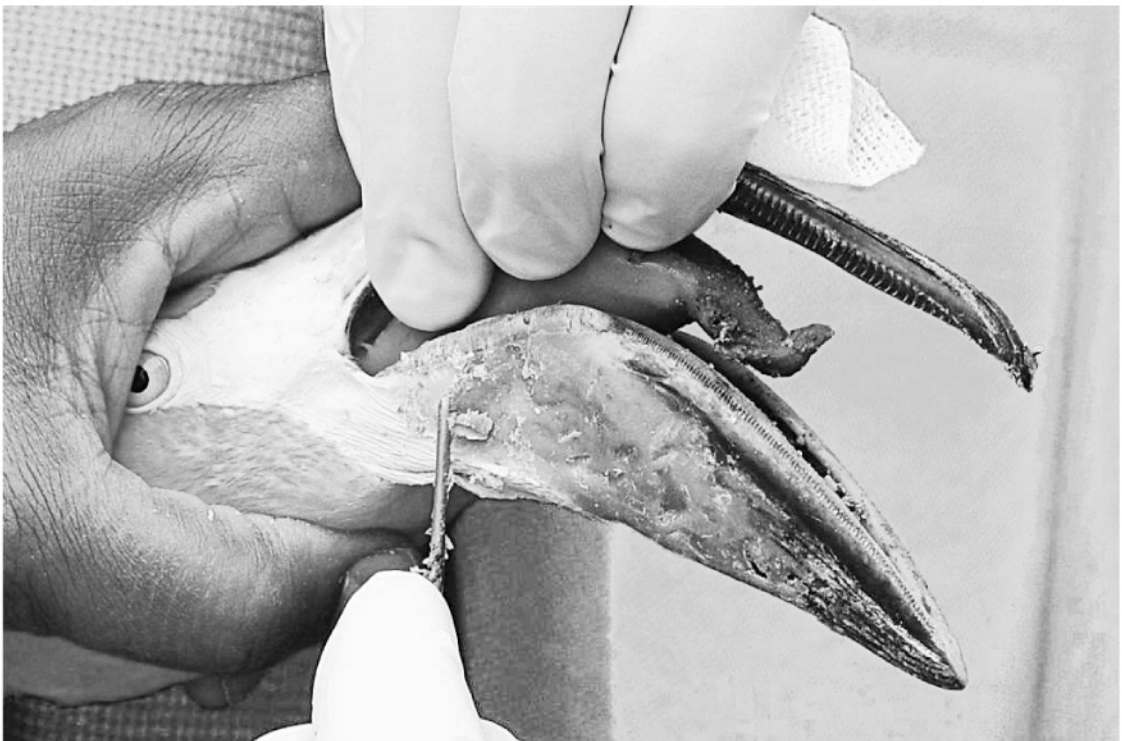

Figure 3. Deformation of the tongue due to a bill impaction with grease and mud in a Caribbean flamingo (*Phoenicopterus ruber*).



Figure 4. Bill impaction with a mixture of grease and mud in a Caribbean flamingo (*Phoenicopterus ruber*).

an irregularly folded tip (Fig. 3). The gular area bulged and was hard on palpation. A blood sample taken from the jugular vein revealed no abnormalities with respect to a complete blood count and a

plasma biochemical panel, except for a low glucose concentration, as compared with reference values⁴ (Table 1). The hypoglycemia was presumed to be the result of reduced food intake.

Table 1. Hematology and serum biochemistry findings in a Caribbean flamingo (*Phoenicopterus ruber*) diagnosed with bill impaction and generalized loss of condition, as compared to reference values.^a

Parameter	Flamingo with bill impaction	Reference values
Packed cell volume (%)	42	38–58
RBC ($\times 10^6/\mu\text{l}$)	3.5	1.1–1.5
Leukocytes (per μl)	10,000	1,500–15,800
Lymphocytes (per μl)	2,300	930–14,500
Heterophils (per μl)	7,400	590–12,500
Monocytes (per μl)	300	3–1,400
Uric acid (mg/dl)	20	4–22
Glucose (mg/dl)	56	107–288
Total protein (g/dl)	4.5	3.2–4.9
Aspartate amino transferase (IU/L)	349	70–476
Lactate dehydrogenase (IU/L)	384	48–697
Creatine kinase (IU/L)	2,000	157–3,521
Calcium (mg/dl)	9.7	5.0–21.8
Phosphorus (mg/dl)	5.9	1.1–6.8

^a No eosinophils, basophils, or thrombocytes were detected in the blood smear.

Treatment

The greasy cover on the outside of the bill and the mass inside the lower mandible were removed manually during manual restraint. The isolated bird was placed in a hospital enclosure lined with mirrors to simulate a flock situation.⁴ The bird was hospitalized for four consecutive days. On the first day, the bird appeared inactive and spent most of the time in a crouching position; however, from the second day on, the bird was active, standing, and was observed eating, drinking, and defecating. Agility improved to the typical level on day 3, and the bird avidly consumed the regular food offered. On the fifth day, the bird was reintroduced to the group. At this time, its body weight had increased to 1.64 kg.

Further cases

After the experience with the first case, the whole group of flamingos was closely observed for similar signs, as the greasy mass was thought to stem from the minced meat mixture offered to the ibises and spoonbills. It was suspected that other flamingos might have ingested this food and that similar complications could potentially occur. Of all of the flamingos, five additional individuals were observed with a swelling of the gular area when compared to the other birds (Fig. 5). The affected birds were caught and manually restrained. On examination, they showed similar but less severe signs compared with those exhibited in the first case, with hard, greasy, black masses of sand, mud, and fat in their lower mandibles. None of the five birds was considered to be emaciated. The birds were immedi-

ately released into the group. No further complications were noted. To prevent future problems, the presentation of the food offered was changed. While the flamingos are continuously fed at ground level, the feeding troughs for the other species are now placed on elevated platforms that are not accessible to the flamingos. No further problems have been noted in the 12 mo following the food presentation change.

DISCUSSION

To our knowledge, this is the first report of a bill impaction in flamingos. It remains unknown why the observed problem occurred for the first time after 8 yr of housing the flamingos in a mixed-species exhibit. We can only speculate that there was a particularly greasy batch of minced meat that triggered the incident.

During routine clinical examinations of flamingos, small amounts of mud or sand can, in our experience, be found in the area underneath the tongue. Usually mud and sand are ejected out of the bill along with water during feeding.⁴ The cases described in this report appear to be rare and most likely occurred because these birds had access to a particularly greasy food mixture, which resulted in a conglomerate of fat and mud in the flamingos' bills that could not be ejected and that built up over time. As the tongues of the affected birds were pushed backwards by the mass, the tongues became immobilized and led to a more pronounced bulging of the gular area. Changes in the gular area could likely have been observed in the first case of this report prior to signs of poor body condition and



Figure 5. Group of Caribbean flamingos (*Phoenicopterus ruber*). Note the bulging of the gular area normally only observed during feeding (arrows) in some birds.

weakness. However, it was only after the clinical examination of this case and a literature search that the relevance of an abnormal extension of the gular area was understood. Our case, therefore, emphasizes the usefulness of anatomic knowledge of species with particular morphologic adaptations.

The quick recovery of the most affected bird and the lack of clinical signs in the other birds after the removal of the impacted masses indicate that the problem was of a mechanical nature. The impacted masses prevented further feeding behavior in the one bird and likely would have caused the same result over time in the other flamingos. The ingestion of food by species other than those for which it is intended is a common problem in mixed-species exhibits, and differences in feeding habits and exhibited use of the different species should be noted and used to avoid this problem. In our case, placing the feeding stations of the other birds on elevated platforms prevented the flamingos from accessing these feeds.

Acknowledgments: We thank HE Sheikh Saoud Bin Mohammed Al-Thani, the owner of Al Wabra Wildlife Preservation, for his continuous support of

scientific work. Our special thanks to Dr. Abdi Arif and Mr. Abid Sharif for performing the laboratory work. The assistance of Al Wabra Bird Department staff involved in the handling of the flamingos is gratefully acknowledged.

LITERATURE CITED

1. Jenkin, P. M. 1957. The filter-feeding and food of flamingos. *Philos. Trans. R. Soc. Lond. B* 240: 401–493.
2. Krumbiegel, I. 1976. *Gefangene Tiere Richtig Füttern*. DLG-Verlagsgesellschaft, Frankfurt/Main, Germany.
3. Mascitti, V., and F. Osvaldo Kravetz. 2002. Bill morphology of South American flamingos. *Condor* 104: 73–83.
4. Norton, T. M. 2005. *Phoenicopteriformes (Flamingos)*. In: Fowler, M. E., and R. E. Miller (eds.). *Zoo and Wild Animal Medicine*, 5th ed. Saunders, St. Louis, Missouri. Pp. 129–135.
5. Wackernagel, H. 1975. Dietary requirements. In: Kear, J., and N. Duplaix-Hall (eds.). *Flamingos*, T. & A. D. Poyser, Berkhamstead, U.K. Pp. 196–198.
6. Zweers, G., F. de Jong, and H. Berkhoudt. 1995. Filter feeding in flamingos (*Phoenicopterus ruber*). *Condor* 97: 297–324.

Received for publication 5 May 2006